

# Detecting aortic valve bicuspidy in patients with severe aortic valve stenosis: high diagnostic accuracy of colour Doppler transoesophageal echocardiography

Rachid Zegdi<sup>a,b,\*</sup>, Vlad Ciobotaru<sup>a,b</sup>, Clémence Huerre<sup>a,b</sup>, Bachir Allam<sup>c</sup>, Nadia Bouabdallaoui<sup>b</sup>, Alain Berrebi<sup>b</sup>,  
Emmanuelle Florens<sup>b</sup> and Jean-Noël Fabiani<sup>a,b</sup>

<sup>a</sup> Université René Descartes, Paris, France

<sup>b</sup> AP-HP; Service de Chirurgie Cardio-Vasculaire, Hôpital Européen Georges Pompidou, Paris, France

<sup>c</sup> AP-HP; Service de Cardiologie, Hôpital Européen Georges Pompidou, Paris, France

\* Corresponding author. Hôpital Européen Georges Pompidou, Service de Chirurgie CardioVasculaire, 20 rue Leblanc, 75015 Paris, France. Tel: +1-56-093748; fax: +1-56092219; e-mail: rzegdi@hotmail.com (R. Zegdi).

Received 7 June 2012; received in revised form 20 July 2012; accepted 31 July 2012

## Abstract

**OBJECTIVES:** The diagnostic accuracy of multiplane bi-dimensional transoesophageal echocardiography (TEE) in detecting aortic valve bicuspidy is good, but is less reliable when the leaflets are moderately or severely calcified. We hypothesized that systolic colour Doppler analysis might improve the accuracy of diagnosing aortic bicuspidy by TEE in patients with severe symptomatic aortic stenosis (AS).

**METHODS:** Two colour Doppler images of a stenotic aortic valve were defined in a preliminary study using multiplane TEE. In type I, the valve opening had a linear, angular or 'hanger-like' configuration and in type II it was more star-like or 'stellar'. The accuracy of this classification in detecting bicuspidy was evaluated. Fifty-one patients (mean age 71 years (range 40–90 years); 52% male) with severe symptomatic AS (defined as aortic valve area  $\leq 1$  cm<sup>2</sup>), requiring surgical aortic valve replacement, were included in this prospective study. The surgical findings were compared with the echocardiographic data.

**RESULTS:** The incidence of aortic bicuspidy was 43%. The presence of type I colour Doppler configuration was significantly higher for bicuspid than for tricuspid aortic valves (95.5 vs 3.5%, respectively;  $P < 0.001$ ). Diagnostic accuracy in detecting bicuspidy was high (sensitivity 95.5%; specificity 96.5%; positive predictive value 95.5%). Intra- and inter-observer agreements were excellent (Kappa coefficient = 0.88 and 0.92, respectively).

**CONCLUSIONS:** Aortic valve bicuspidy may be accurately diagnosed by colour Doppler valve analysis during TEE in patients with severe AS. Larger prospective studies are required to confirm our results.

**Keywords:** Aortic stenosis • Aortic bicuspidy • Transoesophageal echocardiography • Colour Doppler

## INTRODUCTION

Bicuspid aortic valve is a congenital valvular disease with a prevalence of 0.5–1% in the general population [1]. Several surgical series, however, have shown this prevalence to be as high as 49% in patients with severe aortic stenosis (AS) [2]. Until recently, the preoperative detection of aortic bicuspidy in patients with severe AS had limited clinical value. Preoperative diagnosis does not usually affect the technique of valvular replacement other than when concomitant dilatation of the aorta is present [3].

With the recent advent of trans-catheter aortic valve implantation (TAVI), however, accurate preoperative diagnosis of aortic bicuspidy has become a necessity as it is usually considered a contraindication to TAVI [4]. Indeed, stent expansion within a

calcific bicuspid aortic valve differs from that of a tricuspid valve. In the former, the elliptical stent tends to cause valve distortion as previously shown in a human anatomical study [5]. Valve distortion might subsequently be responsible for premature valve failure [6].

Diagnosis of aortic bicuspidy using bi-dimensional transoesophageal echocardiography (TEE) has been shown to be accurate in patients requiring aortic valve replacement. However, accuracy declines in patients with moderately or severely calcified leaflets [7, 8]. A preliminary unpublished investigational study suggested that TEE colour Doppler analysis of the native aortic valve might be of potential interest in detecting bicuspid valves. We report here the findings of a systolic colour Doppler study of native aortic valves along with diagnostic accuracy in patients with severe symptomatic AS.

## METHODS

### Study population

Fifty-one patients (mean age 71 years (range: 40–90 years); 27 males (52%)) were included in this prospective study. The study was approved by the local institutional review board and all patients gave informed consent. All had severe symptomatic AS requiring surgical aortic valve replacement. Preoperative trans-thoracic echocardiographic data are reported in Table 1.

### Multiplane transoesophageal echocardiography examination

All patients had intraoperative multiplane TEE with an IE33 (Philips Healthcare). Colour Doppler scale was  $-61$  to  $+61$  cm/s. Colour gain was reduced to 60%. Frame rate was set at 26 images/s. The TEE study was done in a standard manner. Aortic valves were assessed from the short-axis view. Commissural opening was investigated with colour Doppler. In a preliminary study, each commissural opening was identified as a systolic coloured 'ray' on colour Doppler analysis. A single ray was defined as 'short' when its extension from the centre of the aortic orifice was  $<50\%$  of the distance between this orifice centre and the aortic wall and 'long' if it exceeded 50%.

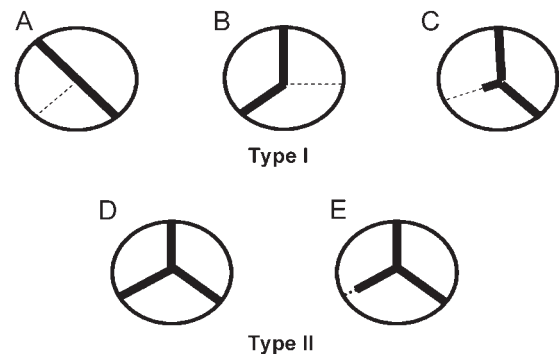
Depending on the number, extent and position of these rays, two types of systolic colour Doppler images of native aortic valves were defined (Fig. 1). In type I, the presence of two or three commissural rays was observed. When only two rays were seen, their spatial orientation was either linear, reflecting the presence of two grossly symmetrical aortic valve leaflets, or angular ('boomerang-like') due to asymmetric leaflets (Figs 1 and 2). When three rays were observed, two of them were considered long while the remaining one was short. In this case, the final colour Doppler aspect was 'hanger-like' (Figs 1 and 2). In type II, three long coloured rays were present giving a 'stellar' aspect to the coloured view (Figures 1–3).

Colour Doppler characterization of the aortic valve was done intraoperatively (prior to sternotomy) by an expert cardiologist who was blinded from the patients clinical data. The surgical team was left unaware of his conclusion.

### Surgical inspection

Surgical aortic valve replacement was performed in a standard manner. Following cardioplegic myocardial arrest, the ascending aorta was opened and the native aortic valve exposed. The valve anatomy was then analysed. When three non-fused commissures were present, delineating three leaflets, the aortic valve was qualified as tricuspid. In 2 cases, a small calcific fusion,  $<2$ -mm long, of one commissure was noticed at the level of the attachment of the leaflet to the aortic wall. This fusion disappeared when the commissure was mechanically opened by gentle stretching of the two adjacent leaflets. These two valves were therefore considered tricuspid. When only two non-fused commissures were present, the valve was considered bicuspid. In these cases, the leaflets were either symmetric or not. To minimize the risk of wrong classification, the characterization of the aortic valve anatomy relied on a consensus between two surgeons.

Final echocardiographic diagnosis of aortic valve morphology solely relied on the colour Doppler aspect of the aortic valve whatever was the impression on 2D analysis. Any aortic valve with a type I aspect on TEE was classified as a bicuspid one. The echocardiographic findings were ultimately compared with the surgical ones. These latter were considered as the gold standard.



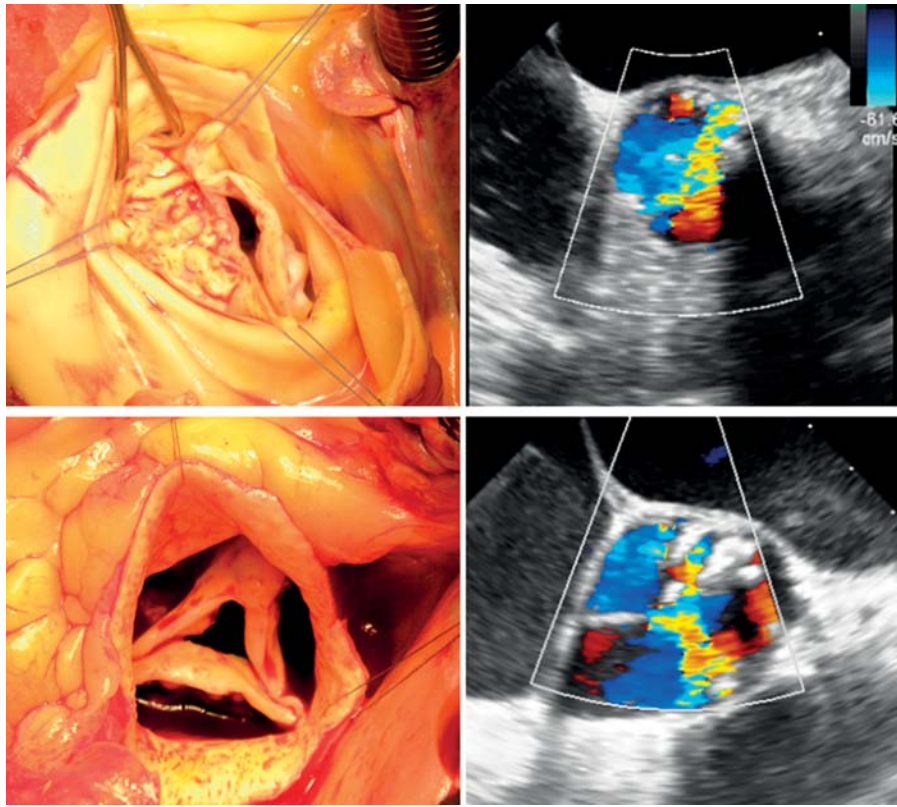
**Figure 1:** Schematic diagram of the systolic colour Doppler aspect of the native aortic valve in patients with severe aortic stenosis. Three aspects, linear or pseudo-linear (A), angular (B) and hanger-like (C) were possible in type I (top). Type II was limited to the complete (D) or incomplete (E) 'stellar' aspect (bottom).

**Table 1:** Preoperative trans-thoracic echocardiographic data according to the study groups

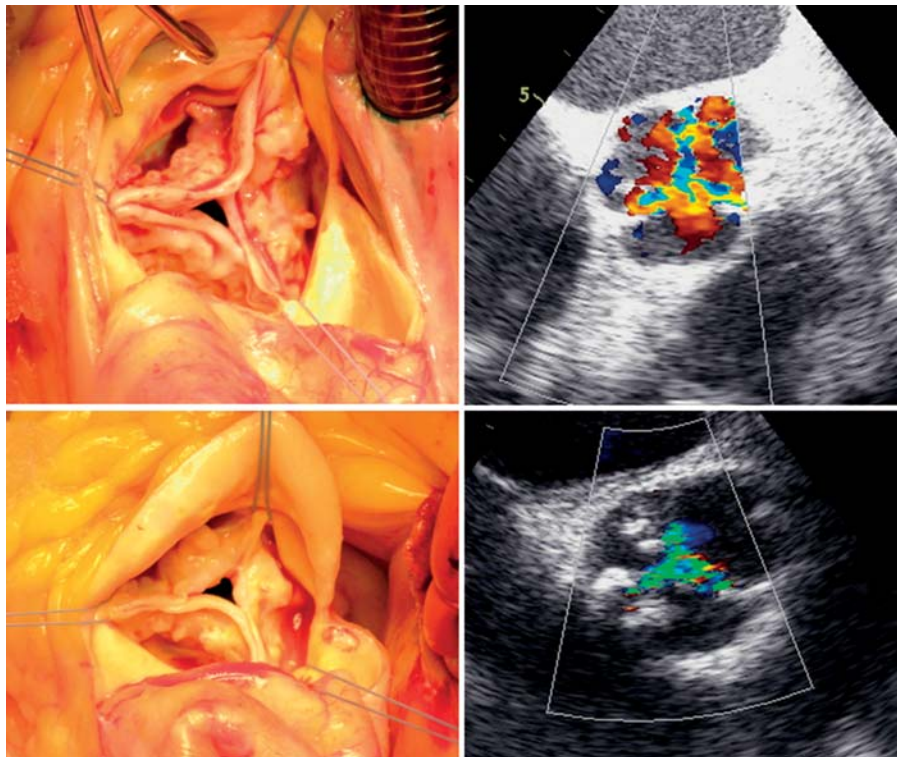
	Population (n = 51)	Bicuspid aortic valve (n = 22)	Tricuspid aortic valve (n = 29)
Aortic valve area (cm <sup>2</sup> )	0.67 (0.3–1)	0.63 (0.36–0.86)	0.7 (0.3–1)
Mean aortic gradient (mm Hg)	53.5 (25–100)	55 (25–85)	52.5 (25–100)
Aortic annulus diameter* (mm)	20 (18–26)	21 (18.4–26)	20 (18–23)
Ejection fraction (%)	61 (20–77)	65 (20–77)	59.5 (25–70)
Ejection fraction $\leq 30\%$	3 (6%)	1	2
Left ventricular end diastolic diameter (mm)	51 (36–65)	53 (41–60)	50 (36–65)
Septal thickness** (mm)	12 (9–18)	13 (10–18)	11 (9–14)

Echocardiographic characteristics were compared between groups of patients with or without a bicuspid aortic valve (results are expressed as n (%) or median (range)).

\* $P < 0.01$ , \*\* $P < 0.05$ .



**Figure 2:** Surgical (left) and colour Doppler (right) views of stenotic bicuspid native aortic valves. Their colour Doppler aspect was linear (top) or hanger-like (bottom) (type I aspect).



**Figure 3:** Surgical (left) and colour Doppler (right) views of stenotic native aortic valves. The aortic valves were tricuspid. Their colour Doppler aspects were 'stellar', either complete (top) or incomplete (bottom) (type II aspect).

## Statistical analysis

Data were expressed as median (range) for continuous variables and as percentage for categorical variables. Comparisons between categorical and quantitative variables were performed with the Fischer's exact or the Mann-Whitney's test, respectively. A *P*-value of <0.05 was considered significant.

All the echocardiographic records were reviewed by the same investigator 2 weeks to 2 months later. Records were also analysed by another expert echocardiographer. Intra- and inter-observer agreements were assessed using the Cohen's kappa coefficient.

## RESULTS

Prevalence of bicuspid aortic valves in our series of patients with severe AS was 43%. Patients with a bicuspid aortic valve were significantly younger than those with a tricuspid aortic valve: 66 years (56–82 years) vs 76 years (60–85 years) (*P* = 0.002). When aortic valve area was determined by the continuity equation, there was no significant difference in severity of AS between patients with or without a bicuspid aortic valve: 0.63 cm<sup>2</sup> (0.36–0.86 cm<sup>2</sup>) vs 0.7 cm<sup>2</sup> (0.3–1 cm<sup>2</sup>) (*P* = 0.8).

There were significant differences in the frequency of type I or type II systolic colour Doppler images of the native aortic valve between patients with or without a bicuspid valve (*P* < 0.001; Table 2).

Type I configuration was observed in 21 of 22 patients with a bicuspid aortic valve. In these patients, the colour Doppler views of the aortic valve were linear, angular or hanger-like in 48, 19 and 33% of patients, respectively.

Type II configuration (i.e. three long coloured rays) was observed in 28 of 29 patients with a tricuspid aortic valve. Partial type II configuration (defined by the presence of a gap of at least 3 mm between the tip of at least one long ray and the aortic wall) was present in 25% of cases (*n* = 7). At surgical inspection, however, a discrete commissural fusion (of <3 mm in length) was seen in only 2 patients (7%) with a tricuspid aortic valve. Rigidity of the leaflets caused by calcific nodules may therefore explain the echocardiographic aspect of incomplete commissural opening in these patients.

One patient with a tricuspid aortic valve had one short systolic coloured ray and was therefore classified as type I. However, retrospectively, a discrete diastolic flow was noted at the level of

the supposedly fused commissure, close to the aortic wall, which goes against the diagnosis of bicuspidy.

In patients with severe calcified AS, TEE diagnosis of aortic valve bicuspidy (based on colour Doppler analysis) had a high diagnostic accuracy (96%), sensitivity (95.5%) and specificity (96.5%). The positive predictive value of a type I image was 95.5%. Furthermore, intra- and inter-observer agreements were excellent with a Cohen's kappa coefficients of 0.88 and 0.92, respectively.

## DISCUSSION

The main result of the present study is that the systolic colour Doppler aspect of the native aortic valve is very accurate (96%) in determining aortic valve morphology in patients with severe symptomatic AS requiring surgical aortic valve replacement.

There are very few studies comparing echocardiographic with macroscopic findings in patients with AS. In a recent study by Makkar et al., the sensitivity and the specificity of multiplane TEE (bi-dimensional study) in detecting bicuspid aortic valves was 89% in patients with moderately or severely calcified AS [7]. In another study, Espinal et al. reported that the sensitivity and specificity of multiplane TEE in detecting bicuspid aortic valves in patients with moderately or severely calcified leaflets were 85 and 88%, respectively [8]. The results of our study, therefore, compare favourably (sensitivity = 95.5%; specificity = 96.5%).

The echocardiographic determination of the morphology of a calcified native aortic valve may be difficult due to artefact generation. In our experience, this is an infrequent condition with colour Doppler analysis in comparison with the 2D study. The reason is that the 'shape' of the trans-valvular flow may be analysed in a plane immediately distal to the free edge of the aortic cusps. This plane is free of nodular calcification. The possibility of evaluating the aortic valve morphology in a plane that does not cross the (calcified) leaflets is a major advantage of the colour Doppler study.

Independently of the intrinsic diagnostic accuracy of the colour Doppler in the detection of bicuspidy, two other factors may explain our excellent results. Firstly, the criteria were determined in a preliminary study of >30 patients. With this experience, interpretation of the data was much easier during the following prospective study (including 51 other patients). Secondly, TEE was performed under general anaesthesia, which facilitated careful valve analysis, especially when evaluation required the commissures to be checked one by one.

In the present study, the detection of bicuspidy relied on the visualization of a systolic colour filling (or a coloured ray) at the level of each commissure. Provided that the probe positioning was correct, it was always possible to decide, by visualizing a commissural coloured ray, whether or not a commissure partially or totally opened. Only 1 patient with a tricuspid valve was wrongly considered as having a bicuspid aortic valve. Correct diagnosis was retrospectively possible by observing, at the level of the apparently fused commissure (close to the leaflets' attachment to the aortic wall), the presence of a diastolic commissural filling. Its presence is incompatible with a commissural fusion. We recommend therefore, also checking the diastolic aspect of the aortic flow in type I aspects.

The systolic colour Doppler images of the aortic valve observed in our study could have been deduced from the results of the anatomic study by Roberts et al. [2]. In bicuspid aortic

**Table 2:** Incidence of transoesophageal echocardiographic systolic colour Doppler aspects of the native aortic valve in patients with severe aortic stenosis requiring aortic valve replacement

Surgical aspect	Echo type I	Echo type II
Bicuspid aortic valve ( <i>n</i> = 22)	21	1
Tricuspid aortic valve ( <i>n</i> = 29)	1 <sup>a</sup>	28

<sup>a</sup>This patient had a diastolic commissural filling at the level of the supposed fused commissure (according to the systolic colour Doppler aspect of the valve).

valves, two main types of leaflet orientation were described: a linear or an angulated one (V-shaped configuration, with the apex of the V pointing toward the raphe). These two configurations were seen in 94% of bicuspid valves. In the remaining 6% of cases, two of the commissures were open, but the last one was partly fused, leading to a hanger-like image.

In tricuspid valves, two types of coaptation lines were observed in Robert's study [2]. In both cases, they more or less resembled a 'Mercedes sign', which is similar to our colour Doppler description ('stellate' configuration). A discrete commissural calcific fusion of  $\leq 3$  mm was seen in 18% of cases. In our study, however, this was only seen in 7% of patients at surgical inspection (2 of 29) and 25% in echocardiographic views.

There are several limitations to our study, primarily with regard to the relatively small sample size of our study population. Therefore, our results have to be confirmed in a larger prospective study. The study was also performed on 51 non-consecutive patients, which may have shown a selection bias. Despite this potential selection bias, the prevalence of bicuspid aortic valves remained high (43%) in our study population as reported in other series of patients with severe AS requiring aortic valve replacement [2]. Furthermore, it is unlikely that the diagnostic accuracy of colour Doppler imaging was affected by potential selection bias due to the design of our study. Indeed, the echocardiographic characterization of each aortic valve was blindly compared with its anatomical aspect.

In the present series, the echocardiographic diagnosis of valve morphology solely relied on the colour Doppler classification, whatever was the 'impression' on 2D analysis. The design of our study, thus, did not allow the comparison of the diagnostic accuracy of the 2D and the colour Doppler analyses in the same population (this would have required a much larger sample size). Demonstrating the superiority of the colour Doppler analysis (against the 2D analysis) is theoretically interesting. The clinical pertinence, however, is doubtful since the 2D valve analysis will remain an integrative part of any aortic valve study (the 2D analysis is mandatory for checking the correctness of the plane used for colour Doppler analysis).

If detecting aortic bicuspidy remains an important issue before TAVI, the place of TEE with colour Doppler analysis during patients' workup has to be determined. On one side, TEE may be poorly tolerated, especially in frail patients. On the other side, multislice computed tomography of the aortic root is required during preoperative evaluation. Its diagnostic accuracy in determining aortic valve morphology (in patients with severe

AS) has been shown to be 98% in a recent series [9]. Therefore, TEE might be proposed to patients with advanced chronic renal insufficiency in whom contrast agents should be avoided.

In conclusion, we have shown that the systolic colour Doppler aspect of the native aortic valve in severe AS can be classified into two basic categories: type I (linear, angular or hanger-like aspect) and type II (stellate aspect). Using this new classification, the diagnosis of bicuspidy was highly accurate (sensitivity = 95.5%; specificity = 96.5%; positive predictive value = 95.5%) in patients with severe AS requiring aortic valve replacement.

**Conflict of interest:** none declared.

## REFERENCES

- [1] Fedak PWM, Verma S, David TE, Leask RL, Weisel RD, Butany J. Clinical and pathophysiological implications of a bicuspid aortic valve. *Circulation* 2002;106:900-4.
- [2] Roberts WC, Ko JM. Frequency by decades of unicuspid, bicuspid, and tricuspid aortic valves in adults having isolated aortic valve replacement for aortic stenosis, with or without associated aortic regurgitation. *Circulation* 2005;111:920-5.
- [3] ACC/AHA. 2006 guidelines for the management of patients with valvular heart disease. A report of the American College of Cardiology/ American Heart Association task force on practice guidelines (writing committee to revise the 1998 guidelines for the management of patients with valvular heart disease). *Circulation* 2006;48:e1-148.
- [4] Vahanian A, Alfieri OR, Al-Attar N, Antunes M, Bax J, Cormier B *et al.* Transcatheter valve implantation for patients with aortic stenosis: a position statement from the European Association for Cardio-Thoracic Surgery (EACTS) and the European Society of Cardiology (ESC) in collaboration with the European Association of Percutaneous Cardiovascular Interventions (EAPCI). *Eur Heart J* 2008;29:1463-70.
- [5] Zegdi R, Ciobotaru V, Noghin M, Sleilaty G, Lafont A, Latremouille C *et al.* Is it reasonable to treat all calcified stenotic aortic valves with a valved stent? Results from a human anatomic study in adults. *J Am Coll Cardiol* 2008;51:579-84.
- [6] Zegdi R, Khabbaz Z, Ciobotaru V, Noghin M, Deloche A, Fabiani JN. Calcific bicuspid aortic stenosis: a questionable indication for aortic valve implantation? *Ann Thorac Surg* 2008;85:342.
- [7] Makkar A, Siddiqui TS, Stoddard MF, Lewis RK, Dawn B. Impact of valvular calcification on the diagnostic accuracy of transesophageal echocardiography for the detection of congenital aortic valve malformation. *Echocardiography* 2007;24:745-9.
- [8] Espinal M, Fuisz AR, Nanda NC, Aaluri SR, Mukhtar O, Sekar PC. Sensitivity and specificity of transesophageal echocardiography for determination of aortic valve morphology. *Am Heart J* 2000;139:1071-6.
- [9] Tanaka R, Yoshioka K, Niinuma H, Ohsawa S, Okabayashi H, Ehara S. Diagnostic value of cardiac CT in the evaluation of bicuspid aortic stenosis: comparison with echocardiography and operative findings. *AJR* 2010; 195:895-9.